



# OPORTO SHOULDER COURSE

CUF Porto Instituto



academiacuf

Formação, Educação e Investigação em Saúde

**26<sup>th</sup> - 27<sup>th</sup> February, 2018**

Smith&Nephew Expert Connect Center, Londres

## CURRENT CONCEPTS IN ROTATOR CUFF REPAIR

**Estado da arte – Reparação da coifa dos rotadores**



# OPORTO SHOULDER COURSE

CUF Porto Instituto



**26<sup>th</sup> - 27<sup>th</sup> February, 2018**

Smith&Nephew Expert Connect Center, Londres

## ESTADO DA ARTE



# Indicação cirúrgica

- **Rotura traumática**

Doente sintomático!

- **Rotura não traumática**

- **Na falência do tratamento conservador**

- Período de reabilitação de 6-12 semanas
  - Agentes físicos e químicos para controlo da dor
  - Alongamento da coifa
  - Reforço estabilizadores escapulotorácicos
  - Reforço rotadores da coifa

- **Rotura reparável**

**Gulotta LV, Curr Rev Musculoskelet Med. 2018**

Arthroscopic rotator cuff repair can decrease pain and increase function allowing patients to improve their quality of life; 90% of patients are happy 6 months after the surgery and maintain stability during 5 years. Greater preoperative expectations would show better outcomes and patient satisfaction after the surgery.

JOURNAL OF  
SHOULDER AND  
ELBOW  
SURGERY

J Shoulder Elbow Surg. 2018 Mar;27(3):444-448. doi: 10.1016/j.jse.2017.10.009.

**What happens to patients when we do not repair their cuff tears? Five-year rotator cuff quality-of-life index outcomes following nonoperative treatment of patients with full-thickness rotator cuff tears.**

Boorman RS<sup>1</sup>, More KD<sup>2</sup>, Hollinshead RM<sup>3</sup>, Wiley JP<sup>2</sup>, Mohladi NG<sup>3</sup>, Lo IKY<sup>4</sup>, Brett KR<sup>2</sup>.

At 5 or more years, all patients were contacted for follow-up; the response rate was 84%. Approximately 75% of patients remained successfully treated with nonoperative treatment at 5 years and reported a mean rotator cuff quality-of-life index score of 83 of 100 (SD, 16).

The operative and nonoperative groups at 5-year follow-up were not significantly different (P = .11).



# Posicionamento do doente

- **Beach-chair**

- **Vantagens**

- Ability to easily convert to an open procedure
    - Limited brachial plexus stress
    - Increased glenohumeral and subacromial visualization
    - Anesthesia flexibility

- **Desvantagens**

- Cerebral hypoperfusion and complications that range from cranial nerve injury to infarction
    - Cervical traction neurapraxia
    - Blindness
    - Cardiac and embolic events

- **Decúbito lateral**

- **Vantagens**

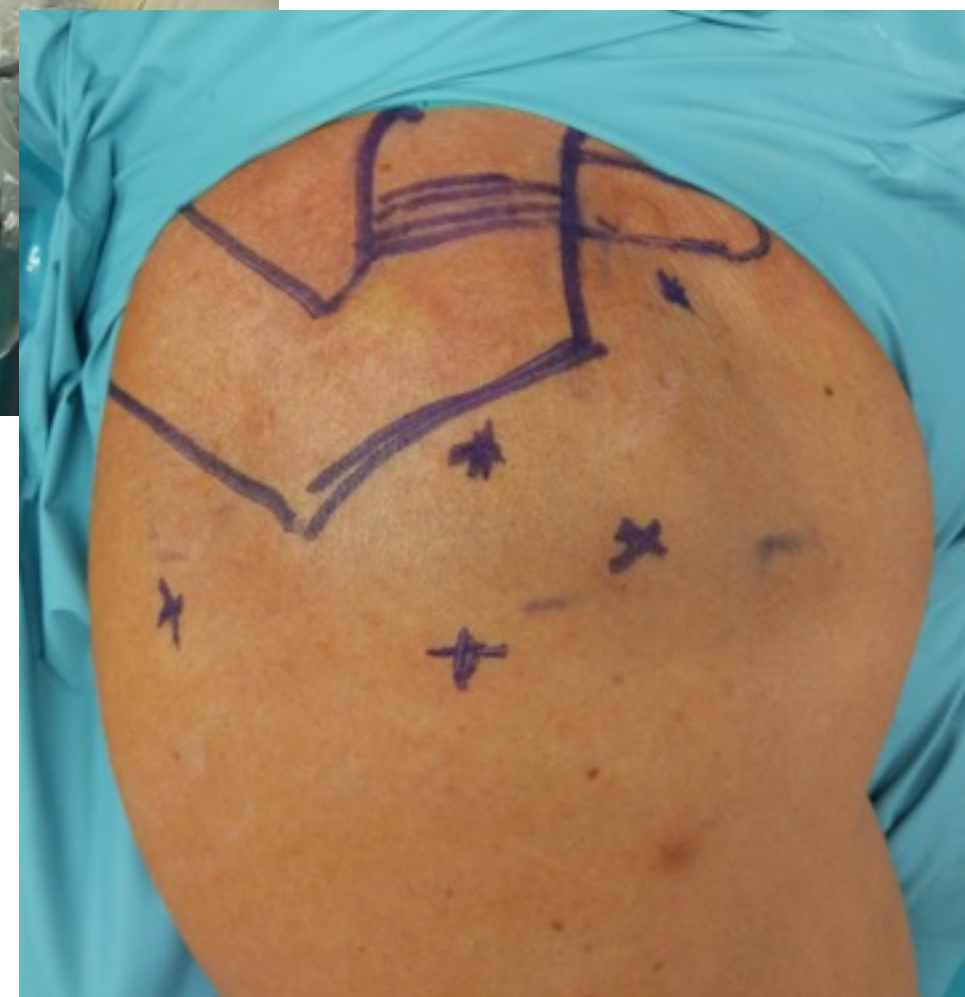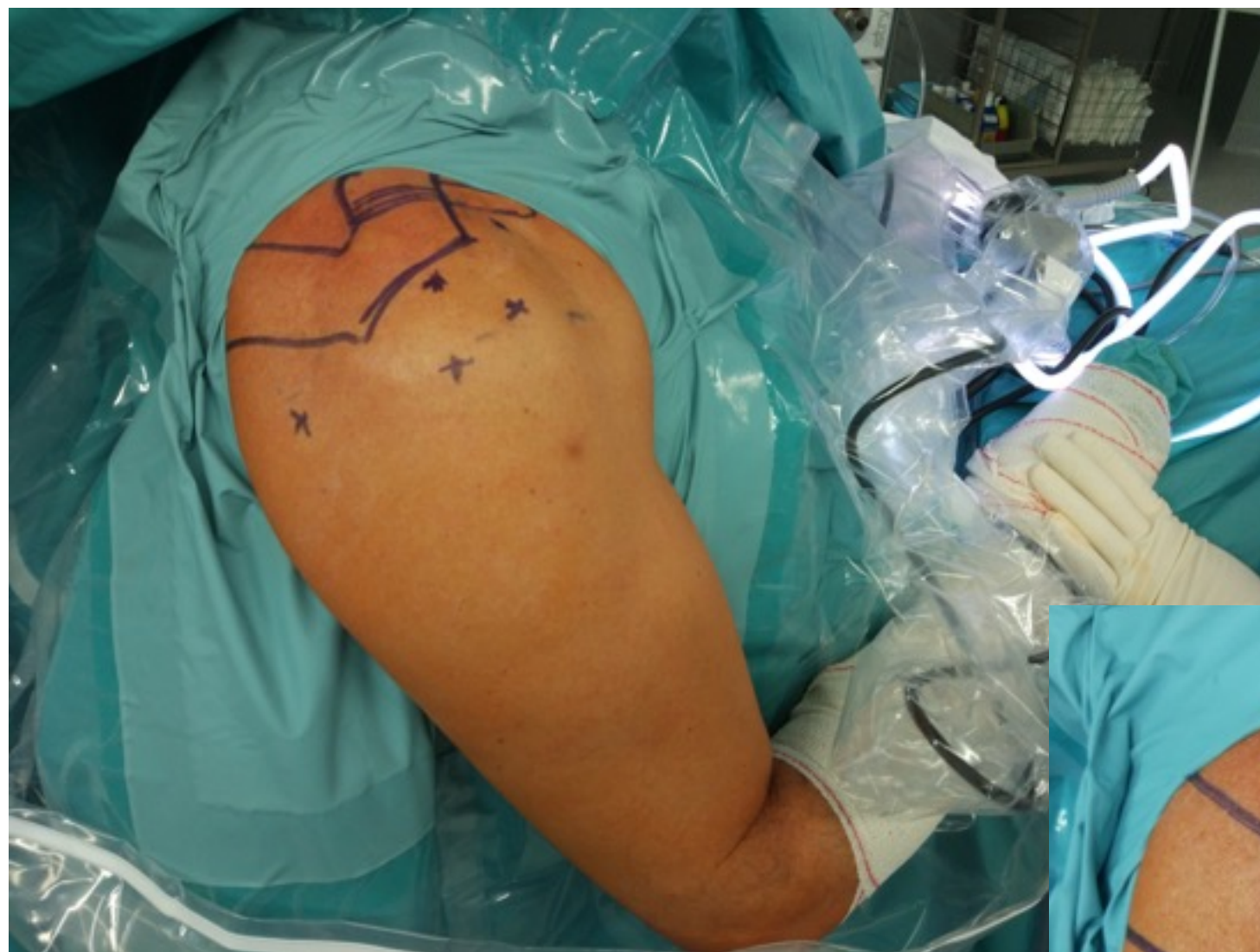- Better visualization
    - Better instrument access for certain procedures
    - Decreased risk for cerebral hypoperfusion

- **Desvantagens**

- Traction injuries (neuropraxia)
    - Thromboembolic events
    - Difficulty with airway management
    - Potential need to convert to an anterior open approach



# Portais utilizados



# Escolha dos implantes

- Âncoras metálicas?
- Âncoras Bio-absorbable poly-L-lactic acid (PLLA)?
- Âncoras Non-absorbable polyetheretherketone (PEEK)?
- Âncoras tecidulares?
- Sem âncoras (transósseo)?
- Fios ou fitas?





# Escolha dos implantes



## Bioabsorbable versus Metal

Bioabsorbable implants have many advantages over metal implants, including:

- 1 Load sharing versus stress shielding
- 2 Reduced risk of articular damage
- 3 MRI compatible for Post-Op diagnosis
- 4 Minimised risk of obstruction during revision surgery if required
- 5 Minimised risk of stress risers normally associated with implant removal.

*Shoulderdoc*

*Orthop J Sports Med.* 2017 Jul; 5(7): 2325967117717010.  
Published online 2017 Jul 20. doi: [10.1177/2325967117717010](https://doi.org/10.1177/2325967117717010)

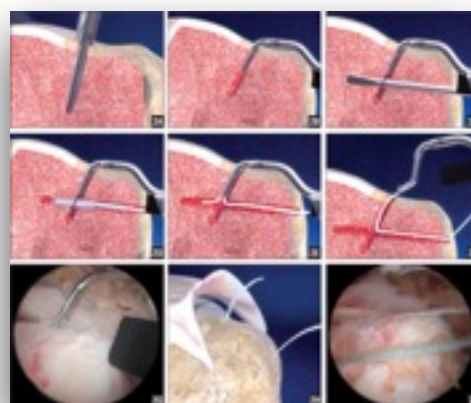
PMCID: PMC5524240

## Biomechanical Comparison of a First- and a Second-Generation All-Soft Suture Glenoid Anchor

John Erickson, MD,<sup>\*†</sup> Frank Chiarappa, MD,<sup>†</sup> Jonathan Haskel, MD,<sup>†</sup> Justin Rice, MS,<sup>†</sup> Adam Hyatt, MD,<sup>†</sup> James Monica, MD,<sup>†</sup> and Aman Dhawan, MD<sup>‡</sup>

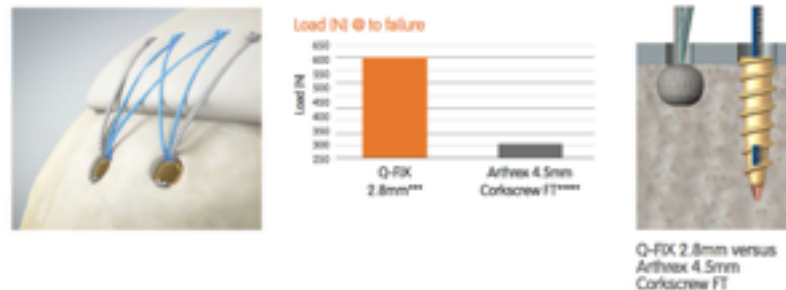
(1) first-generation all-soft suture anchor (Juggerknot; Biomet), (2) second-generation all-soft suture anchor (Suturefix; Smith & Nephew), and (3) a control PEEK anchor (Bioraptor; Smith & Nephew)

The newer generation all-soft suture anchors with a theoretically more rigid construct and deployment configuration demonstrate biomechanical characteristics (specifically, with load to 2-mm displacement after cyclic loading) that are improved over first-generation all-soft suture anchors and similar to a traditional solid tap-in anchor.



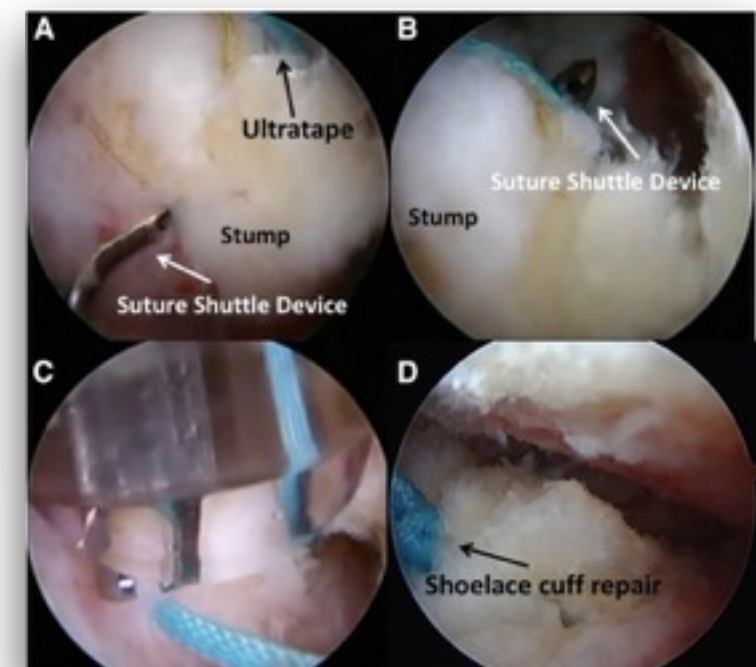
## Rotator cuff repair

The 2.8mm Q-FIX implant's fixation performance and small footprint makes it a great option for rotator cuff repair. With performance similar to traditional corkscrew anchors more than twice the size, the 2.8mm Q-FIX is ideal for medial row fixation where performance is needed and space is limited.



No statistically significant difference in initial fixation stability between the new type anchor and titanium screw anchor. The new type of suture anchor constructed of cortical bone provides comparable initial fixation strength to a similar metallic anchor for rotator cuff repair

*Liu Y, Int Orthop. 2016*

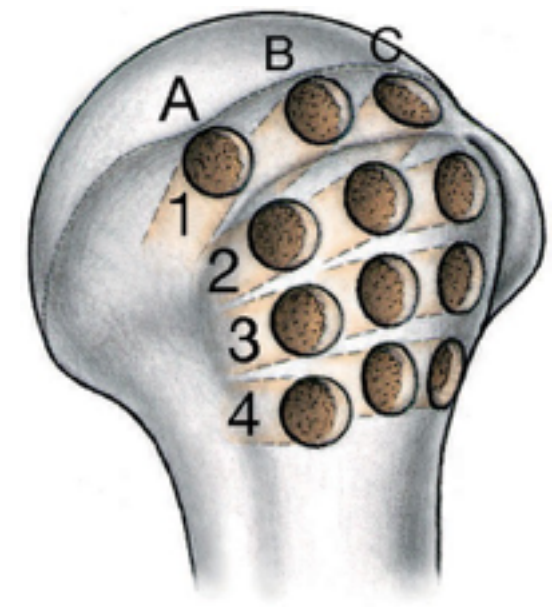


# Local de colocação dos implantes

- **Distribuição equitativa**
- **Bom stock ósseo**
- **Distância mínima**

For the 2 tested anchors (Metal screw-type anchors and PEEK (polyether ether ketone)), the minimum distance between the anchors without decreasing the pullout strength was 6 mm (center to center) regardless of bone density in a biomechanical study.

Itoi E, Arthroscopy. 2018



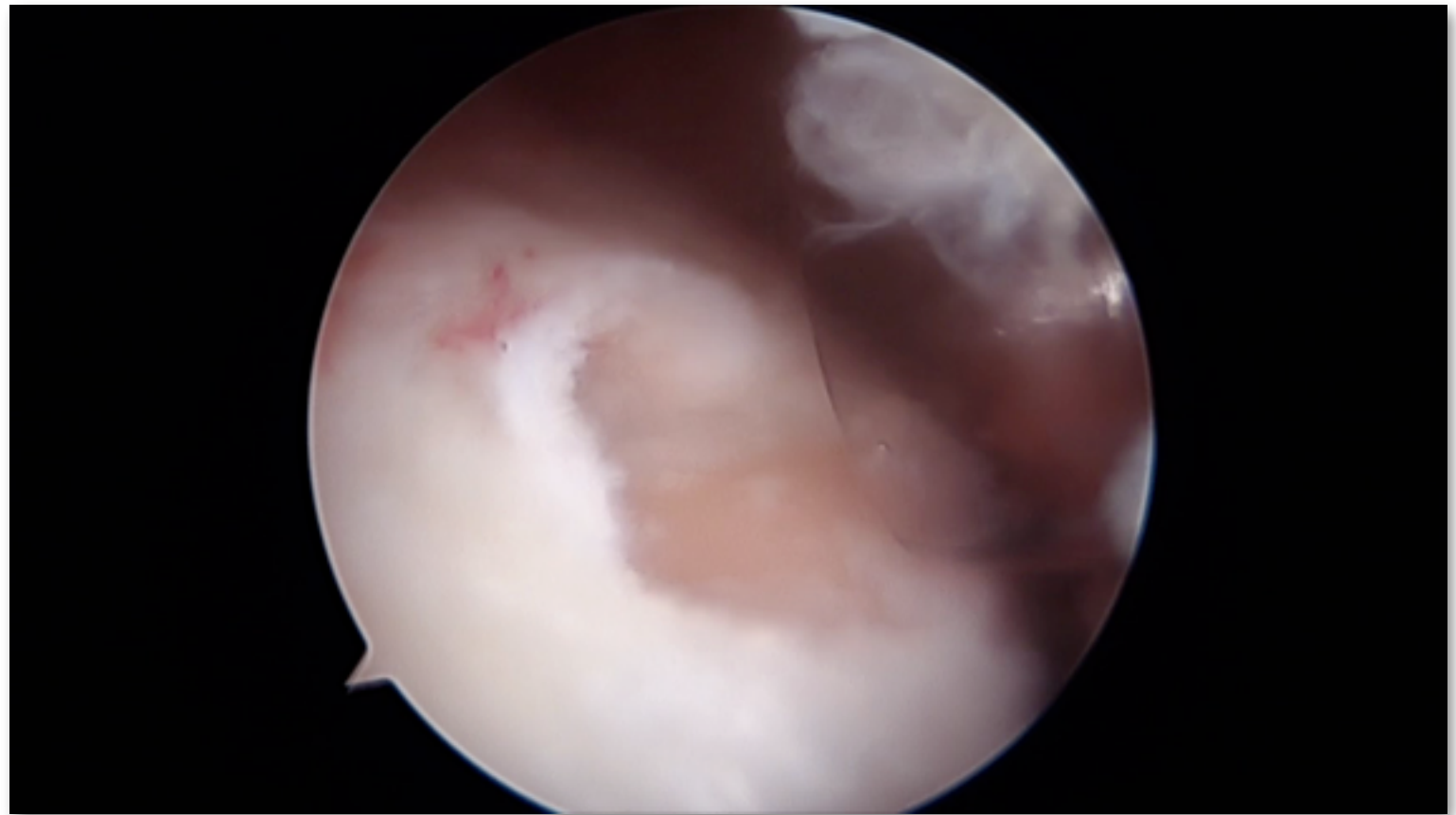
The inferior-most lateral row, 15 to 21 mm from the tip of the GT, has good bone stock, the greatest cortical thickness, and the best SMI for lateral row anchor placement. The anterior-most part of the GT 15 to 21 mm below its summit had the greatest cortical thickness of all zones. The posterior third of the GT also has good bone stock parameters, second only to the medial row. The best site for lateral row cortical anchor placement is 15 to 21 mm below the summit of the GT.

Zumstein MA, Orthop J Sports Med. 2016



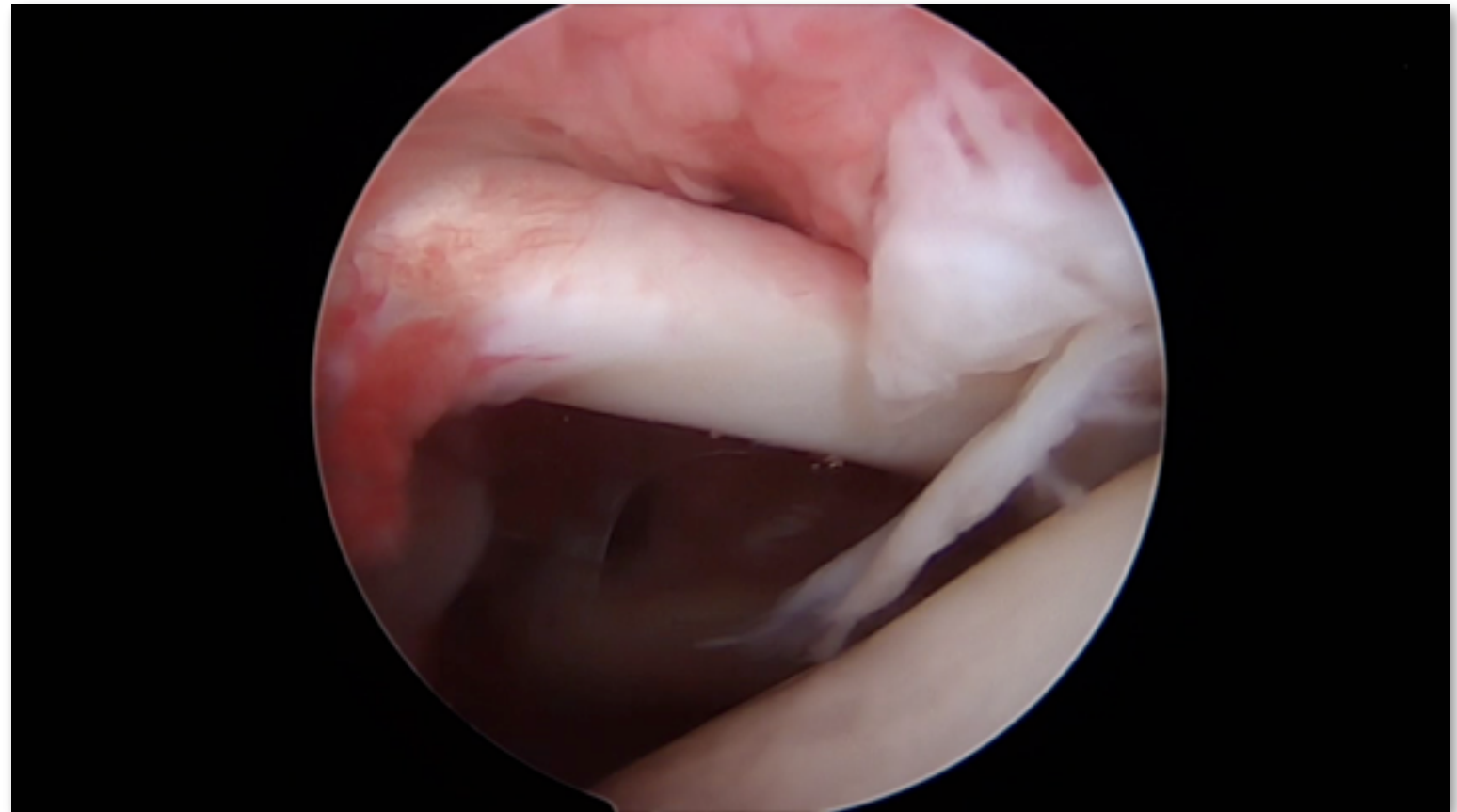
# Tipos de reparação

- **Single row**
- **Double row**
- **Suture bridge**
- **Shoelace Side-to-Side Repair**



# Tipos de reparação

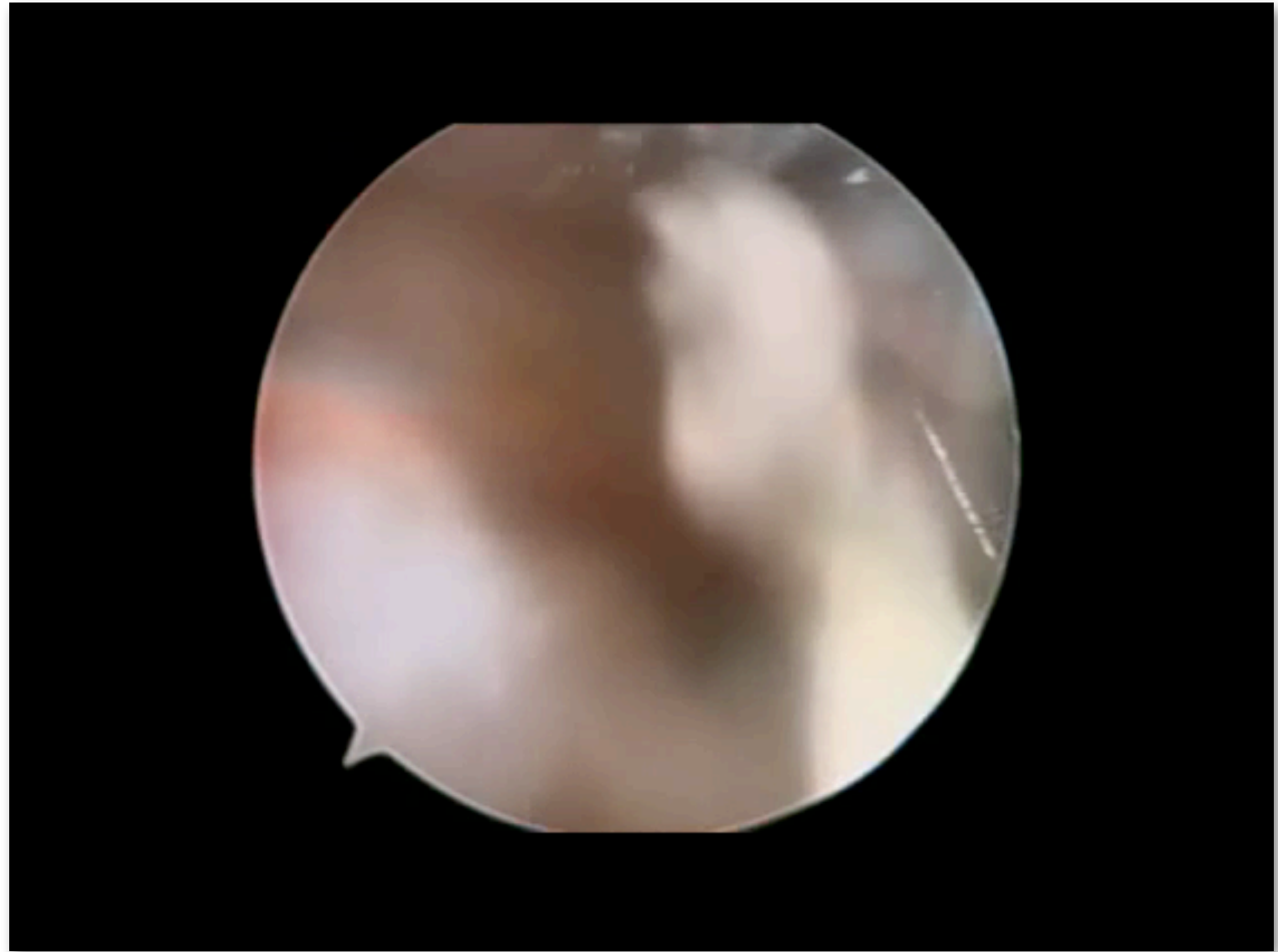
- Single row
- **Double row**
- Suture bridge
- Shoelace Side-to-Side Repair





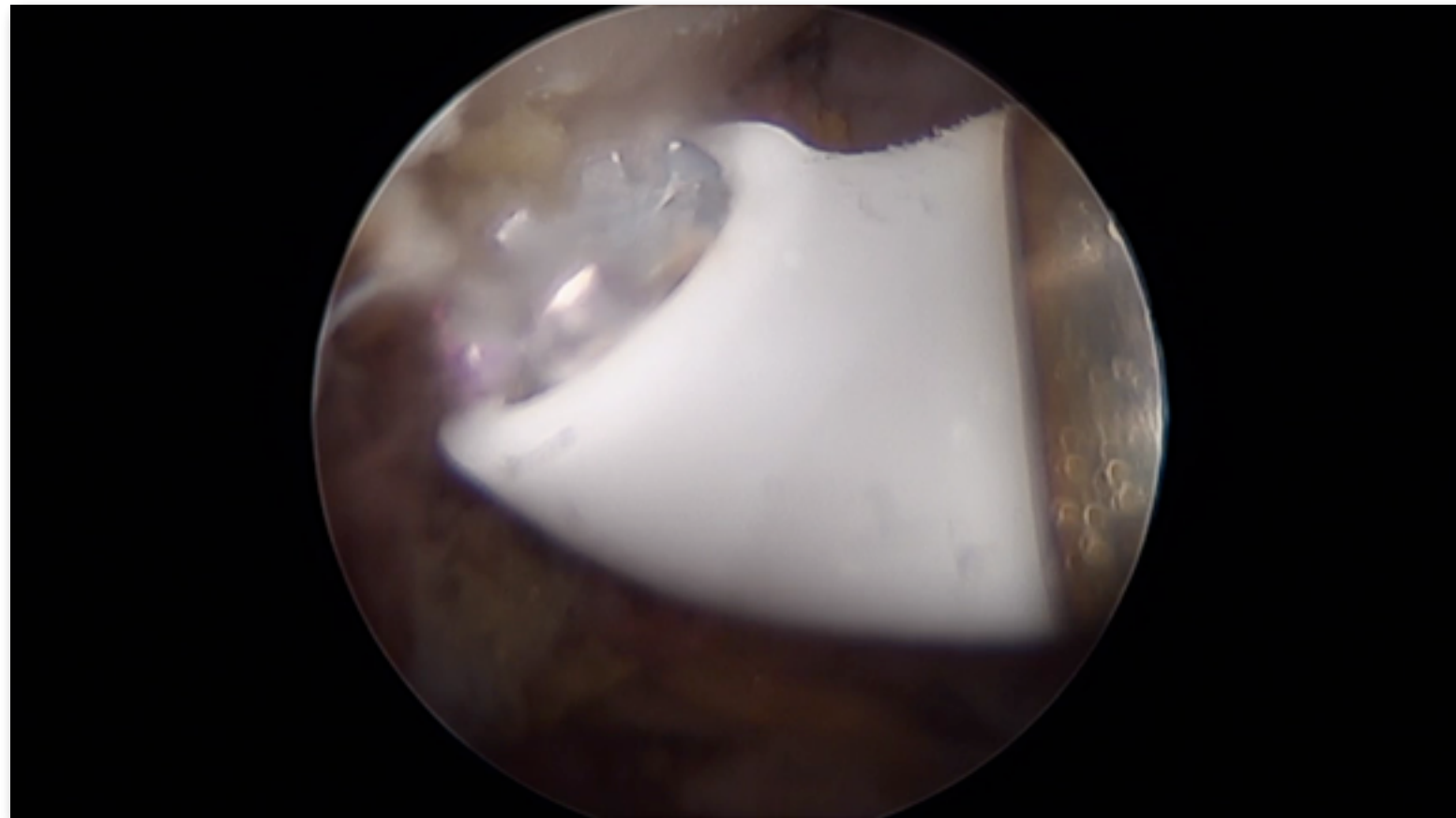
# Tipos de reparação

- **Single row**
- **Double row**
- **Suture bridge**
- **Shoelace Side-to-Side Repair**



# Tipos de reparação

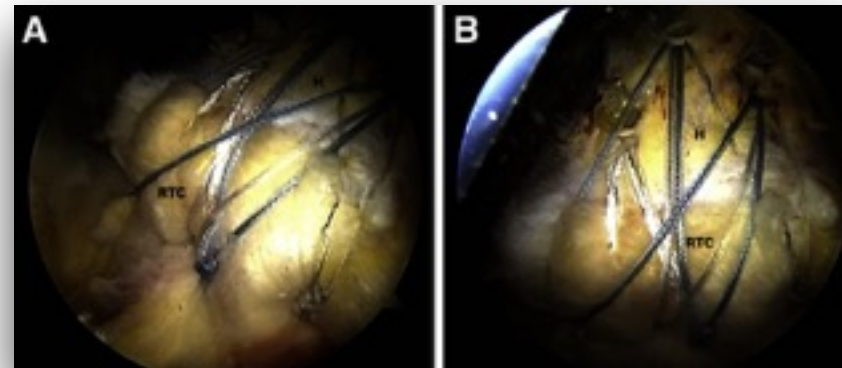
- **Single row**
- **Double row**
- **Suture bridge**
- **Shoelace Side-to-Side Repair**



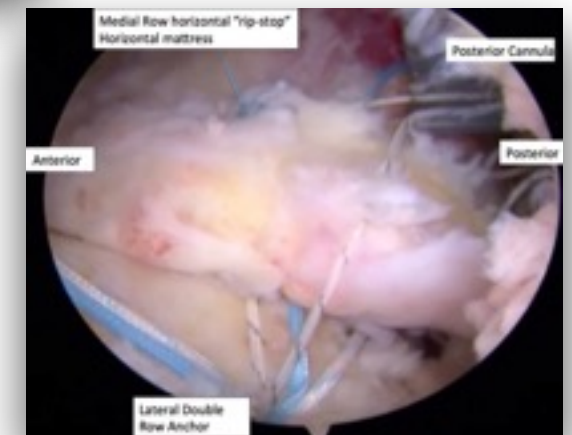
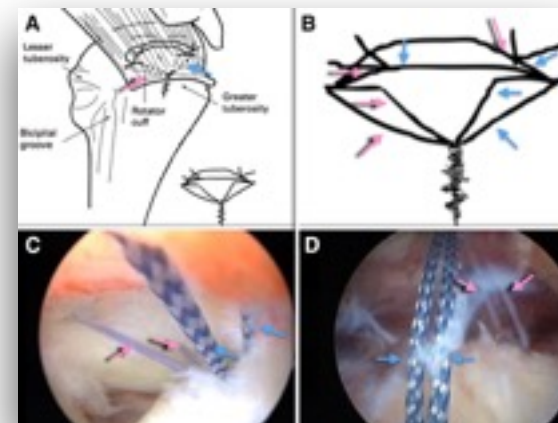


# Tipos de reparação

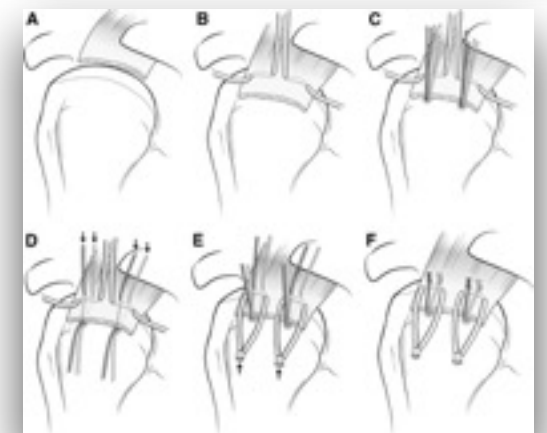
- **Triple row**



- **Double-Row Rip-Stop**



- **"Parachute" Technique**



- **Dual rip-stop rotator cuff repair**

Rotator cuff repair under arthroscopy has a reliable clinical effect for the patients with rotator cuff tears. Stable and reliable clinical results can be obtained regardless different repair methods or different rotator cuff tears

There is no statistical difference in load to failure and cyclic loading between Triple-Loaded Suture anchor and Knotless Rip Stop Construct in a Single-Row repair techniques

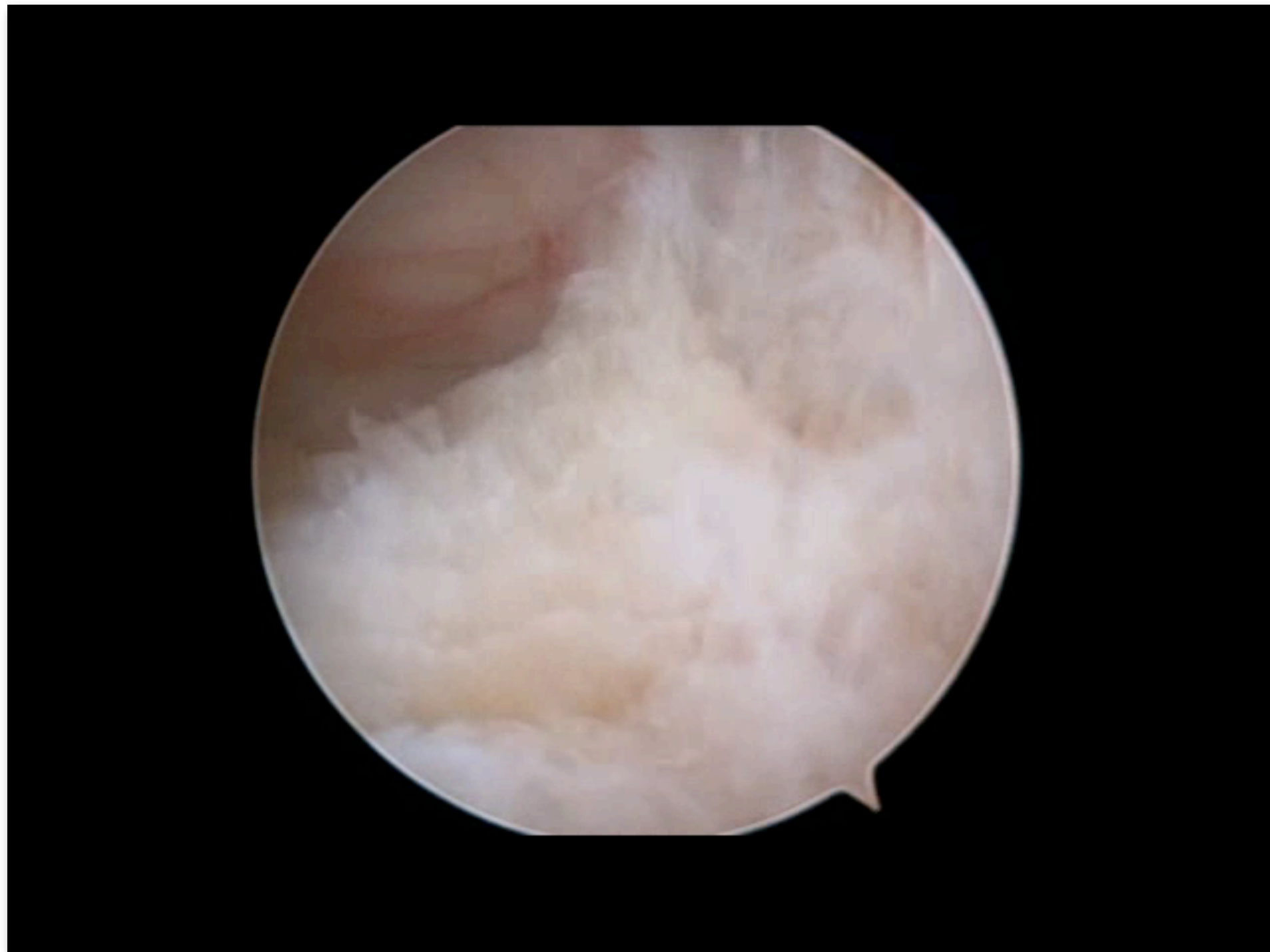
Denard P.J., Arthroscopy. 2018

There was no significant difference in peak load at failure, stiffness, maximum displacement at failure, or mean bone mineral density among the 5 suture configuration groups

Esquivel AO, Orthop J Sports Med. 2015

# Reparação do subescapular

- **Reparar primeiro!**







# Gestos associados

- **Tenodese / Tenotomia LPB**
- **Acromioplastia**
- **Abertura do intervalo dos rotadores**
- **Labrum**



# Protocolo de reabilitação pós-operatório

- **O meu protocolo**

- Imob 3 sem (susp braq c banda toracica)
  - Mob passiva
    - Cotovelo
    - Pendulares
    - RE/RI
- 3 - 8 sem: mobilização activa assistida
- 8 - 12 sem: mobilização activa
- >12 sem: reforço muscular





# OPORTO SHOULDER COURSE

CUF Porto Instituto



**26<sup>th</sup> - 27<sup>th</sup> February, 2018**

Smith&Nephew Expert Connect Center, Londres

## A MINHA TÉCNICA

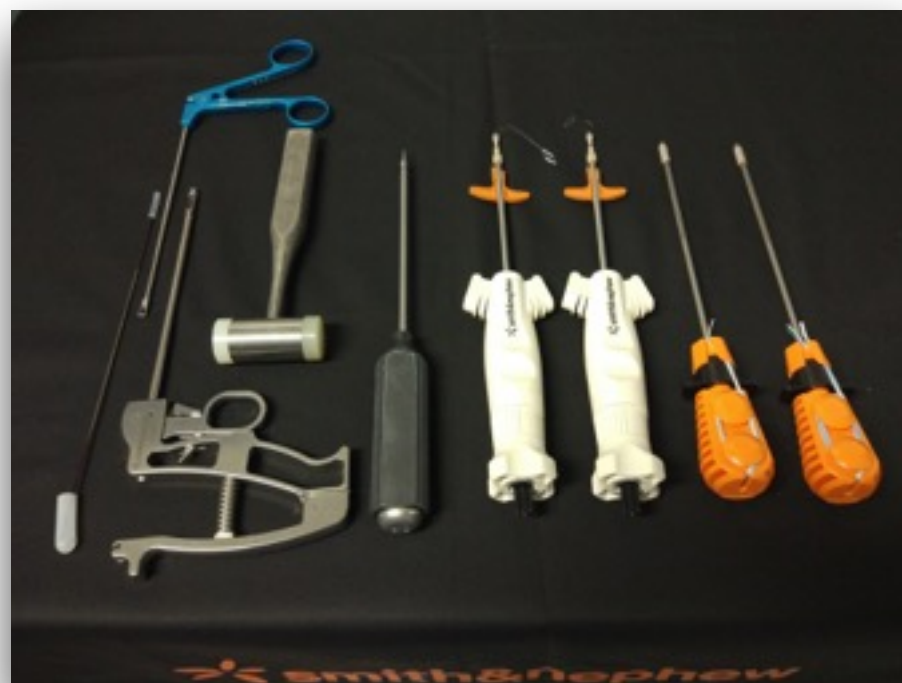




# Dupla Fileira “mista”

- **Vantagens**

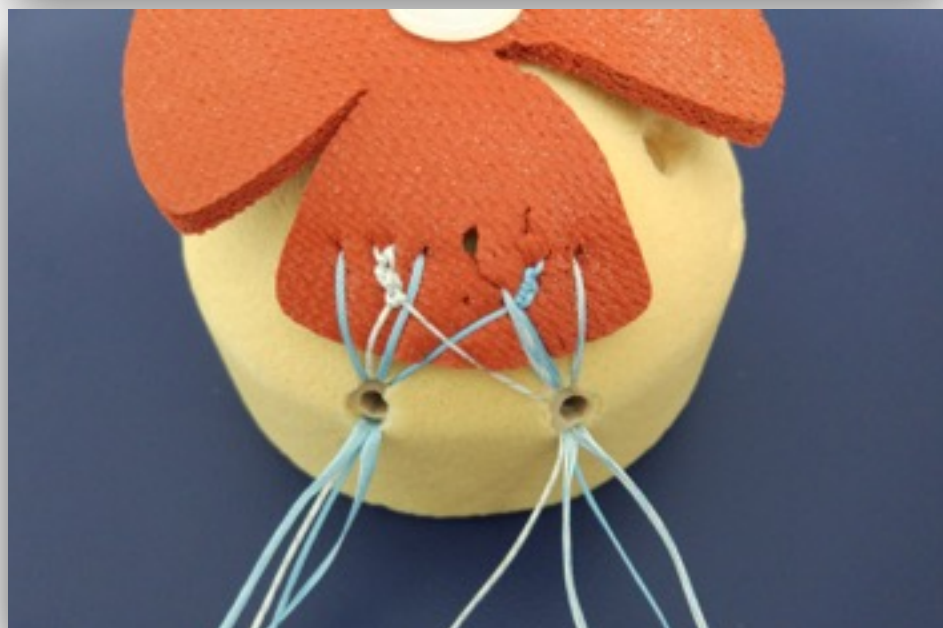

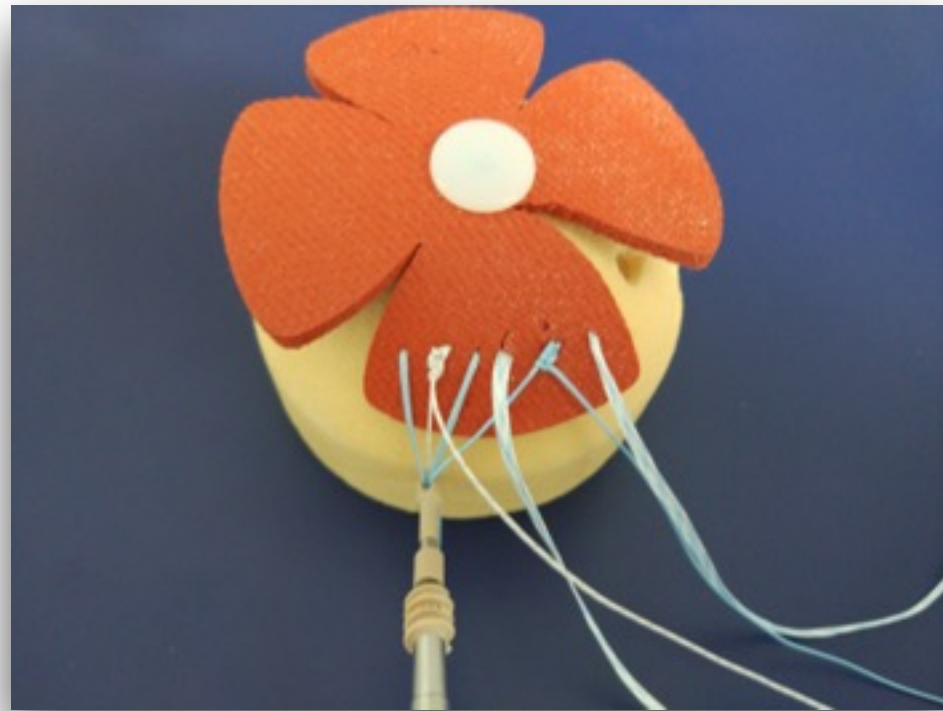
- Melhor distribuição dos fios /fitas
- Melhor tracção do tendão
- Pontos de fixação medial
- Tensão não depende apenas da fileira lateral
- Rapidez

# Dupla Fileira “mista”

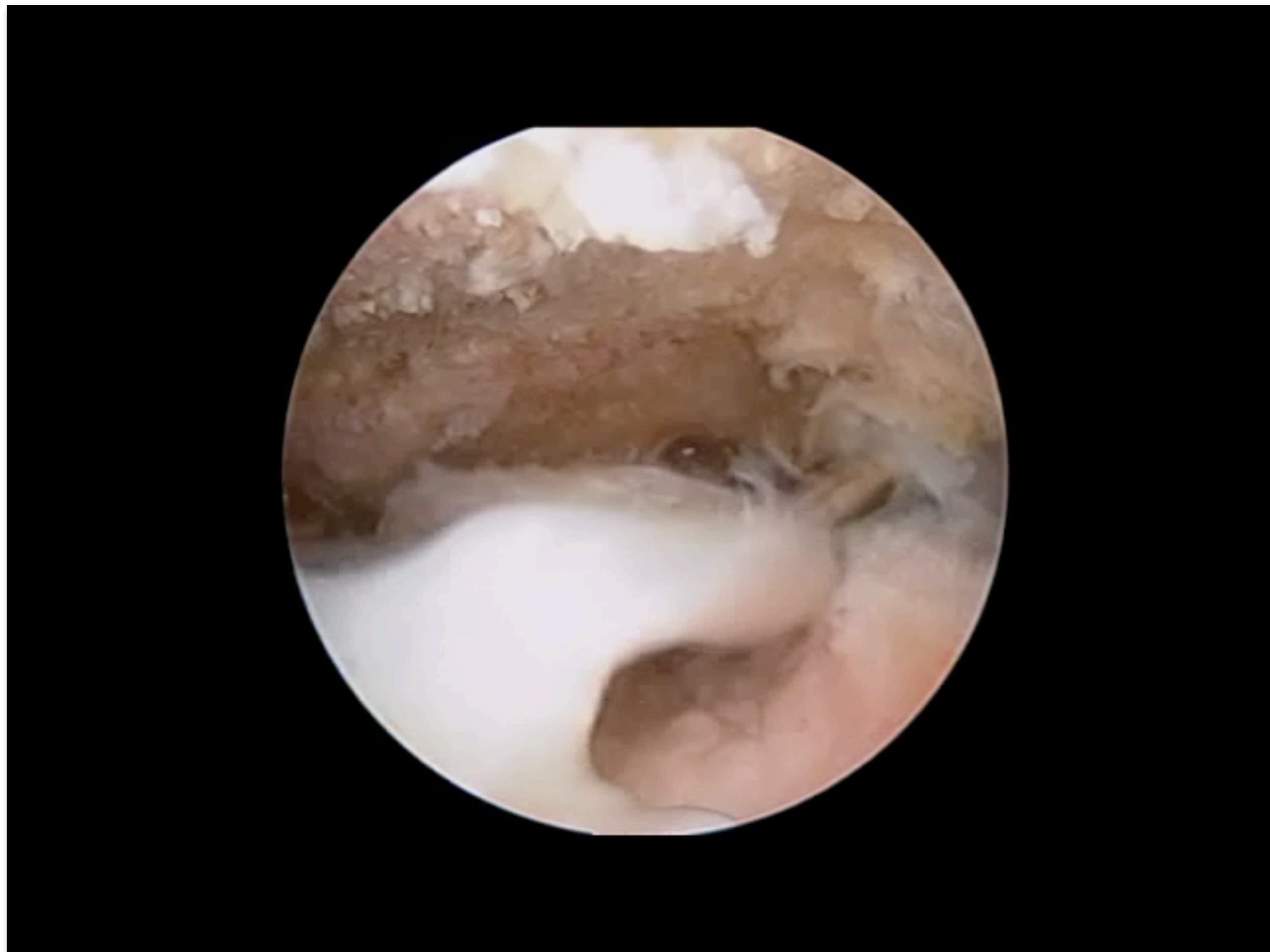





## Dupla Fileira “mista”

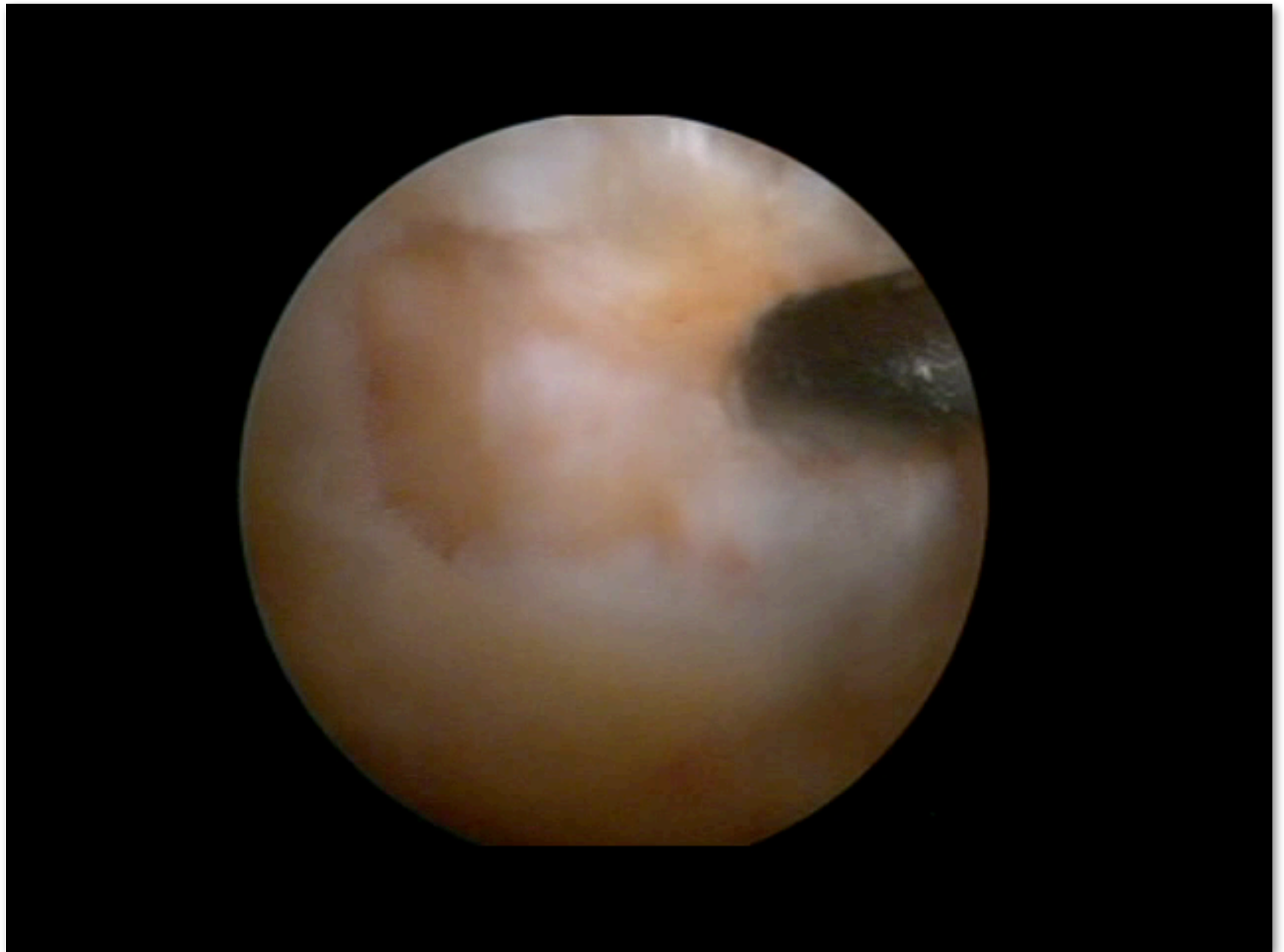


## Dupla Fileira “mista”






## Dupla Fileira “mista” 2 Anch





## Dupla Fileira “mista”



• 4 meses pos-op



# OPORTO SHOULDER COURSE

CUF Porto Instituto



**26<sup>th</sup> - 27<sup>th</sup> February, 2018**

Smith&Nephew Expert Connect Center, Londres

# OBIGADO